CIRC

CIRC
Center of Interdisciplinary Research on Compression
Amraserstrasse 85, A - 6020 Innsbruck

CIRC meeting 2019

**Bologna, Italy**
**October 25-26, 2019**

Hotel I Portici Bologna
*www.iporticihotel.com*

*Compression and Inflammation*

**Local Organizer:**
Ursula Partsch
Tagungsmanagement
www.tagungsmanagement.org
Tel: +43 2672 889 96

WWW.CIRC-RESEARCH.COM

# Compression in inflammatory complications in lymphedema

F.-J.Schingale, MD



**CIRC-Meeting 2019, Bologna, Oct. 25-26, 2019**

# Disclosure

- No conflict of interest
- Travel expenses and accomodation are payed by CIRC

# Inflammation and compression: the state of art

Daniela Ligi, Lidia Croce, Ferdinando Mannello
Department of Biomolecular Sciences, University of Urbino Carlo Bo, Urbino (PU), Italy
*Veins and Lymphatics 2016; 5:5980*

In this regard, **inflammatory processes** by leukocytes and macrophages affect the venous endothelium, promoting a complex succession of events involving the activation of adhesion molecules, chemokines, cytokines, growth factors, and proteases which cause endothelia dysfunction and dysregulation, compromisin tissue integrity and finally **lead to dermal damage and ulcer development.**

**In fact compression therapy** has been widely recognized as the **cornerstone for CVI and ulcer healing.**

# Inflammation in Lymphedema

**Skin injuries** with subsequent superinfections lead to edema progression.
Therefore wounds should be treated as soon as possible with disinfectant externa (for example Polyvidon, Octenidine).
The same applies to **ruptured cysts and fistulas**.
**Interdigital macerations** due to tinea pedis and manum as well as **bacterial superinfections** have to be treated according to the trigger.
In case of **eczematoid changes, allergic reactions or insect bites** transient local therapy with steroids may be required.

# Inflammation in Lymphedema

- Eczema
- Folliculitis
- Fungal infections
- Lymphangiectasy
- Papillomatosis
- Cysts and Lymphorrhoea
- Ulceration
- Erysipelas
- Radiodermatitis and Radiofibrosis
- Malignoma

# Skin changes







# Dermato-Lymphangio-Adenitis (DLA) (before: Erysipela)

- is a common and serious complication of obstructive peripheral lymphedema
- The clinical characteristics of acute DLA are local tenderness and erythema of the skin, sometimes red streaks along the distribution of the superficial lymphatics and enlarged inguinal lymph nodes.
- Systemic symptoms include malaise, fever and chills.
- Each episode of DLA is commonly followed by worsening of leg swelling.
-

**Olszewski WL**., Lymphology. 1996 Sep;29(3):126-31.

# DLA

# DLA

# cellulitis necroticans

# inflammatory stimulus

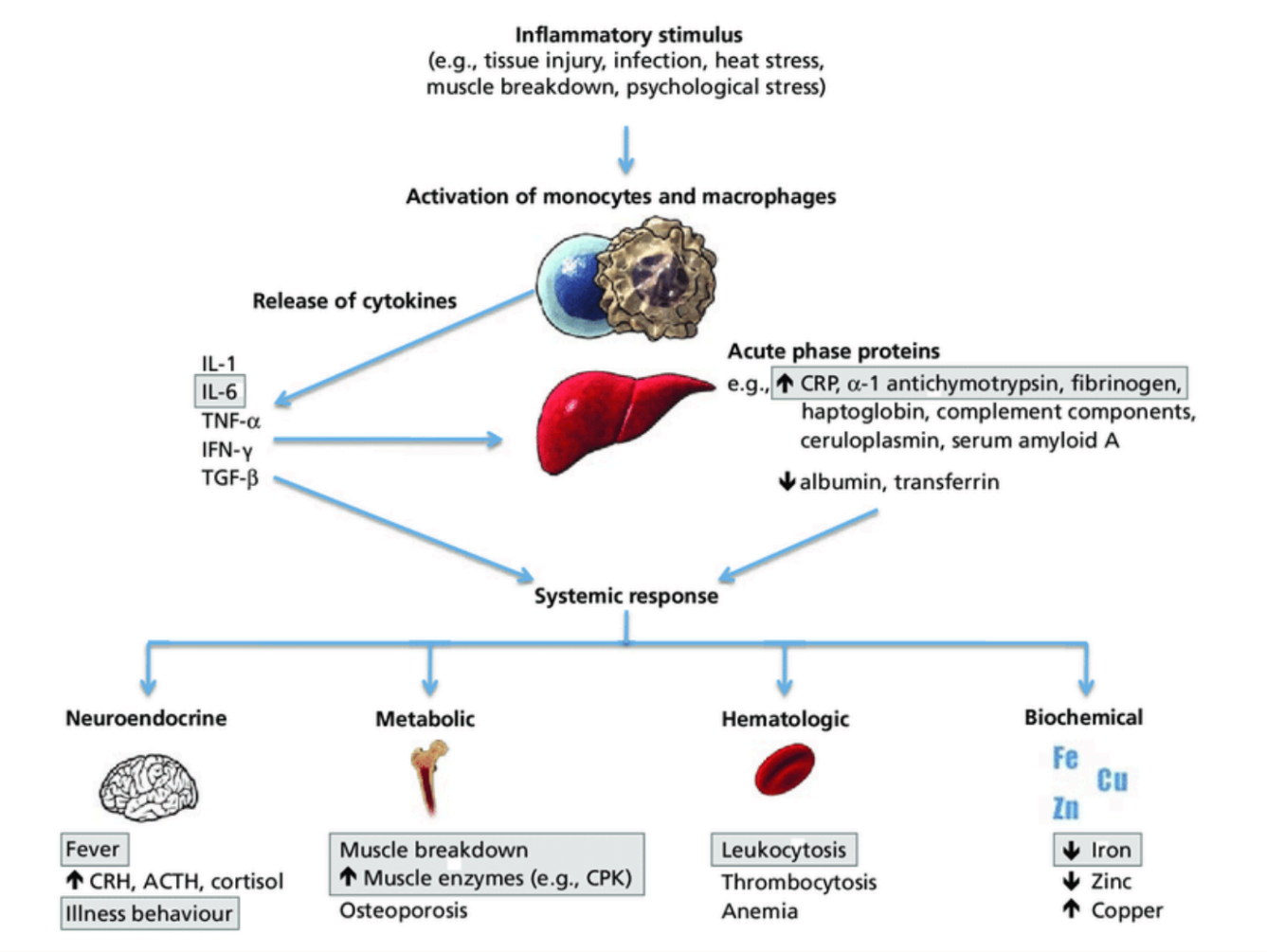

# Acute Phase Response

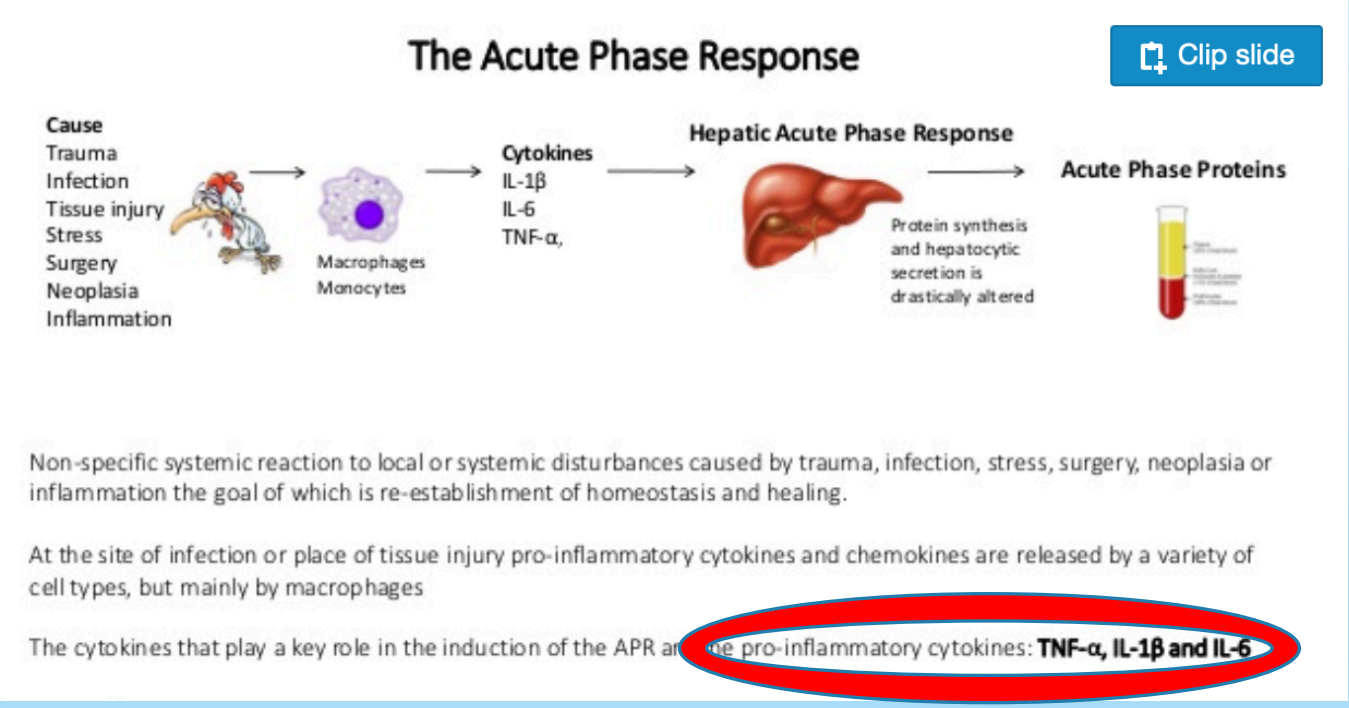

# effects of acute phase response (APR)

- The effects of APR are both: local and systemic.
- **local effects** are intended to limit possible infections and eliminate xenobiotics. Dead or damaged cells are eliminated by phagocytosis and repair processes are initiated.
- **systemic effects** are defense reactions that are intended to ensure the survival of the entire organism, for example against endotoxins. The systemic effects include a number of "side effects" such as increased body temperature, an increase in white blood cell count, anorexia and depression

# what does compression do?

- decreases filtration rate
- Reduction of venous reflux
- Improvement of venous pumping function
- Reduction of ambulatory venous hypertension
- Increase of arterio-venous pressure gradient
- Shift of fluid into non-compressed parts of the body
- Improvement of lymphatic drainage
- Improvement of microcirculation
- Breakdown of fibrosclerotic tissue (increased mobilisation)
- effect on ultrastructures and cytokines

# Compression is important in erysipelas treatment

not in acute but for recurrency

**[Compression is important in erysipelas treatment].**

[Article in Danish]

Villefrance M[1], Høgh A, Kristensen LH.

**Author information**

1 maja.villefrance@hotmail.com.

**Abstract**

Erysipelas is a common skin infection involving the lymphatic vessels, which induces an oedema. This has a tendency of persisting after infection is treated. The lymphatic system plays an important role in the immune system, and the impaired lymph drainage leads to a state of local immune [illegible] esis of recurrent erysipelas, as each episode of erysipelas further damages the lym[illegible] system and increases the risk of a new [illegible]n. This vicious circle makes it important to treat both erysipelas and oedema ap[illegible]riately to reduce recurrence and morbidity.

# prophylaxis

Loïc VAILLANT

*Université François Rabelais,*
*Tours, France*

**SUMMARY**

Erysipelas is a nonnecrotizing bacterial hypodermal cellulitis usually associated with streptococcal infection. It may be a mainly secondary complication of chronic lymphedema, and occurs in 20% to 30% of cases.
The first presenting signs are sudden fever and shivering. The clinical feature is inflammatory plaque, which is often chronic and accompanied by fever. Inflammatory plaque is promoted by lymph stasis, and is marked by inflammatory episodes that often regress spontaneously.
Erysipelas per se is mainly treated with antibiotics, and adjuvant therapies are not justified. The prevention of recurrence is primary. Since lymphedema is the first risk factor for recurrence, the prevention of recurrence must be considered. This includes physiotherapy, well-adapted compression therapy, and avoidance of wounds.

# Compression

- compression has antiinflammatory properties and is also indicated in dermato-lymphangio-adenitis (erysipel/cellulitis), which used to be contraindications in the past.

# Compression and deep vein thrombosis

- Compression may have two beneficial effects in deep vein thrombosis (DVT): i) long term use may reduce the incidence and severity of a post-thrombotic syndrome (PTS); in the acute stage it alleviates pain and swelling.
- Hugo Partsch, Veins and Lymphatics 2016; volume 5:5991

# RICE

- Rest, ice, **compression**, and elevation (RICE) are generally accepted methods for treating **inflammation** after trauma, such as acute ankle sprain. … Accumulation of fluid and edema around an injury site also increases tissue damage, delays healing, and can result in some degree of chronic disability.

- There is significant evidence showing that certain cytokines/chemokines are involved in not only the initiation but also the persistence of pathologic pain by directly activating nociceptive sensory neurons

  Jun-Ming Zhang, MSc, MD and Jianxiong An, MSc, MD, Int Anesthesiol Clin. 2007 Spring; 45(2): 27–37.

- Reducing the biological activity of proinflammatory cytokine can reduce the brunt of attack from diseases.

# Compression controls edem

- Well, according to Knight (1995), compression helps control edema formation and reduces the swelling by promoting reabsorption of this fluid.
- Not only does the compression aid reabsorption, it shuts down the area and therefore will not allow for additional edema to formulate.
- If there is less tissue debris, there is less free protein which will lower the tissue oncotic pressure.
- Tissue oncotic pressure pulls fluid from the capillaries and will increase edema (Knight, 1995).
-

# Compression

- It helps to prevent blood clots, which is why **compression** therapy is frequently advised following surgery.
- Improving venous flow speeds up wound **healing** and assists in preventing infection.
- Since **compression** limits swelling, it **can** also minimize edema around the wound
- Pain and swelling are minimized,

# Compression

- Swelling caused by infection increases pressure in the tissues and leads to higher pressures than normal under **compression**.
- If a decision is made to continue compression during **cellulitis**, patients need close monitoring until the swelling and **cellulitis** is under control.

# AWMF Guideline S2k Guideline 31.12.2018 Medical Compression Therapy of Extremities with Medical Compression Stocking (MCS), Phlebological Compression Bandages (PCB) and Medical Adaptive Compression Systems (MACS)

- **8.1.4 Improvement of ulcer healing**
- PCB are considered the standard therapy for venous ulcer cruris but also MCS and MACS are suitable for ulcer therapy.
  - Blecken and coworkers were able to show that, compared to a 4-component PCB, treatment with MACS led to a significantly faster reduction in wound size.
  - Partsch and Horakova were able to show that MCS and PCB led to a comparable ulcer healing rate (1994).
  - Jünger showed in 2004 that special bilayer ulcer compression stocking systems led to better healing than standard PCB.
  - Ashby randomized 457 ulcer patients into a group with a 4-component PKV and a group with a 2-layer ulcer compression stocking system. The cure rate was virtually identical

# AWMF Guideline S2k Guideline 31.12.2018 Medical Compression Therapy of Extremities with Medical Compression Stocking (MCS), Phlebological Compression Bandages (PCB) and Medical Adaptive Compression Systems (MAS)

- **8.2 DVT**

  In acute deep vein thrombosis (DVT) **compression** therapy has a **long tradition** as a supplement to anticoagulation. In particular, it plays an important role in the early mobilization and outpatient treatment of DVT.
- **8.2.1.1 Initial pain and edema reduction**
- **8.2.1.2 Reduction of thrombus mass**
- **8.2.2 Superficial venous thrombosis**

  In a recent Cochrane review on the treatment of superficial venous thrombosis OVT), compression therapy was included as a standard treatment in addition to other measures.

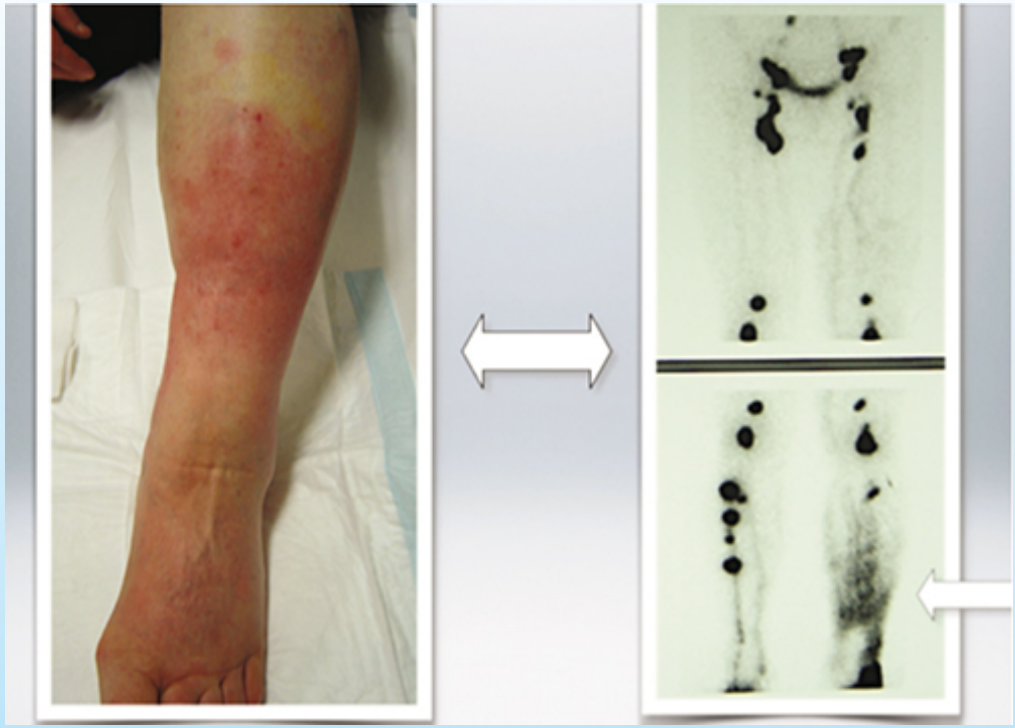

**Alberto Macciò, Jun 14 2016** demonstrates clearly that the inflammation of the skin of the lower leg lymphedema completely disappeared under the bandage while it is still visible in the proximal parts of the limb.

# our results

Zinc-Alginat(Unna boot) bandage for 24 h


# and use of CircAid


# Newest case

born 1981
height 172cm
weight 290,6kg
swelling of scrotum started 4 years ago


# one day with Unna boot


# S2k Leitlinie Diagnostik und Therapie der Lymphödeme AWMF Reg.-Nr. 058-001

Mai 2017

**7. Was sind absolute und relative Kontraindikationen der Komplexen Physikalischen Entstauungstherapie (KPE) oder einzelner Komponenten?**

Absolut: Dekompensierte Herzinsuffizienz, akute tiefe Beinvenenthrombose, erosive akutes schweres Erysipel, pAVK Stadium III / IV.
Relativ: Malignes Lymphödem, Hautinfektionen, Hauterkrankungen (z.B. blasenbildende Dermatosen), pAVK Stadium I/II. Ggf. sollte eine stationäre Einleitung der Therapie erfolgen.

**Zustimmung 96,9% (starker Konsens)**

**Erysipelas**: should be systemically treated with an antibiotic. Until the onset of antibiotic activity, **no KPE should be given to the affected limb**, depending on the general condition and condition of the skin.

# conclusion I

- lymphedema is a chronic disease that affects a considerable number of patients. The swelling results in pain, impaired function and reduced quality of life.
- recurrent infections exacerbate lymphedema and lead to further episodes of erysipelas, creating an inevilable spiral of decline.
- specialized physicians and therapists provide advice and treatments that significantly improve patient outcome and quality of life.....

# conclusion II

- Compression in acute dermato-lymphangio-adenitis is not anymore an absolute contraindication
- the inflammation doesn‘t grow,
- acute phase response is reduced
- reduction of edema by reduction of CFR
- reduction of pain

# Thank you for your attention